

Histological Effects of Carotenoid On Carbon Tetrachloride Induced Hepatotoxicity In Adult Wistar Rats.

Ezejindu D.N.^{*1}, Okafor I. A.¹, Anibeze C.I.P.², Ihentuge C.J.³

¹ Department of Anatomy, College of Health Sciences, Nnamdi Azikiwe University, Nnewi, Anambra state, Nigeria.

² Department of Anatomy, College of Health Sciences, Abia State University, Uturu, Abia state, Nigeria.

³ Department of Anatomy, College of Health Science, Imo State University Owerri, Imo state, Nigeria.

ABSTRACT; This work focuses primarily on the effects of carotenoid on carbon tetrachloride induced hepatotoxicity in adult wistar rats. Twenty four wistar rats weighing between 100-200g were used. The rats were divided into four groups of six animals each. The groups were designated as A, B, C, and D. group A served as the control and received 0.35ml of distilled water. Group B received 0.41ml of carotenoid, group C received 0.41ml of carbon tetrachloride and group D received 0.41ml of carotenoid + 0.41ml of carbon tetrachloride. The drugs were administered orally once in a day using intubation method for a period of 21 days. Twenty four hours after the last administration, the animals were anaesthetized under chloroform vapor and dissected. Liver tissues were removed, weighed and trimmed down to a size of 3mm×3mm tick and fixed in zenkers fluid for four hours for histological studies. The relative liver weight for group c were significantly higher ($p < 0.001$) than the control. The values for group B and D increased significantly relative to the control. Histological analysis revealed distortions of liver tissues in group C when compared with the control. The result revealed that antioxidant property of carotenoid exhibited a liver protective effect against carbon tetrachloride induced hepatotoxicity.

KEYWORDS: Carotenoid, Hepatotoxicity, Carbon tetrachloride, Liver weight, Wistar rat

I. INTRODUCTION

Carotenoids are used as antioxidants which help to protect against free radicals that attack molecules of cells. They are fat soluble compounds formally called lipochromes. Their significance is attributed to their well documented antioxidant properties. Their antioxidant effect enables this compound to play crucial role in protecting organism against damage during photosynthesis^[11]. Carotenoids generally cannot be manufactured by species in the animal kingdom so animals obtain carotenoids in their diets. People consuming diets rich in carotenoid from natural foods, such as fruits and vegetables, are healthier and have lower mortality from a number of chronic illnesses^[5]. The liver play a central role in the metabolism of many drugs and induced hepatic injury is now one of the commonest forms of iatrogenic disease. Indeed, in any patient presenting with obscure liver diseases or unexplained jaundice, the possibility of a drug induced lesion should always be considered. Many of the pathological features such as hepatocellular injury and necrosis, hepatitis both acute and chronic and jaundice by various mechanisms can be reproduced by drugs^[6]. In this research work, carbon tetrachloride will be used to induce liver injury in rats. Exposure to Carbon tetrachloride results mostly from breathing air, drinking water coming in contact with soil that is contaminated with CCl₄. CCl₄ is a well known hepatodestructive agent that is widely used to induce acute toxic liver injury in a range of laboratory animals^[10]. CCl₄ has caused cancer in animals exposed to it as a result of exposure to a very high amount^[3,9,11]. Epidemiological studies have shown that people with high beta-carotene intake and high plasma level of beta-carotene have a significantly reduced risk of lung cancer. Lycopene and beta-carotene taken along with Vit C and D helps to protect the body against the effect of chemotherapy and radiation^[12]. The aim of this study is to evaluate the histological effects of carotenoid on carbon tetrachloride induced hepatotoxicity in adult wistar rats

II. MATERIALS AND METHOD

2.1 BREEDING OF ANIMALS

Twenty four Wistar rats were purchased from the animal house of the Anatomy Department, University of Calabar, Cross River State, Nigeria. They were bred in the experimental animal house of University of Uyo Akwa Ibom State and allowed for a period of five days for acclimatization under normal temperature (27^oC - 30^oC) before their weights were taken. They were fed ad libitum with water and guinea feed pellets from Agro feed mill Nigeria Ltd. Perspex cages were used to house groups of six (6) animals for routine experiment.

2.2 DRUG PREPARATION

The drugs used for this research work include the following as stated below: Commercial carotenoid was obtained from Golden Neo-life Diamite (GNLD) Int, Spartan by pharmaceutical contractors Isando Road, Isando, South Africa and purchased from No. 6 Itu Road, Uyo retails outlet, Akwa Ibom State, Nigeria. One Capsule of carotenoid containing 900mg was dissolved in 10mls of distilled water and administered to the animals. Carbon tetrachloride was obtained from the Department of Biochemistry, University of Calabar, Cross Rivers State, Nigeria.

2.3 EXPERIMENTAL PROTOCOLS

The twenty four animals were weighed and allocated into six groups of four animals each. The groups were designated as groups A, B, C, and D. Group A animals served as the control and received 0.35ml of distilled water. The experimental groups B, C and D received different doses of drugs as follows: Group B received 0.41ml of carotenoid. Group C received 0.41ml of CCl₄, Group D received 0.41ml of carbon tetrachloride (CCl₄) and 0.41ml of carotenoid. The drugs were administered once in a day for a period of twenty one days. The drugs were administered orally using intubation method. After the twenty first day, the animals were weighed and their weight recorded. Twenty four hours after the last administration, the animals were anaesthetized under chloroform vapour and were dissected. Liver tissues were removed from the animals and weighed. They were trimmed down to a size of 3mm x 3mm thick and fixed in zenkers fluid for four (4) hours for histological and histochemical studies. The tissue slides were prepared in the histology laboratory, Anatomy Department, college of Basic Medical Sciences, University of Calabar.

2.4 TISSUE PROCESSING

For easy study of sections under microscope, the tissues passed through several processes of fixation, dehydration, clearing, infiltration, embedding, sectioning and staining. The tissues were trimmed down to a size of about 3mm x 3mm thick and fixed in zenkers fluid. After fixation, dehydration of the fixed tissues was done in ascending grades of alcohol 50%, 70% and 95% absolute and cleared in xylene. Staining was done with heamatoxyline and eosin and mounted using DPX. After which, the sections were viewed under the light microscope.

III. RESULT

3.1 PHYSICAL AND BEHAVIOURAL CHANGES. At the beginning of the experiments, all the animals looked healthy and agile. During the one weeks of acclimatization, their stools were normal. On administration of carbon tetrachloride, varying gradations of toxicity were observed. Generally, the signs of toxicity observed include:

- a) Labour breathing
- b) Staggering / loss of balance
- c) Convulsion
- d) Decreased food intake

These signs were not observed following administration of carotenoid.

3.2 MORPHOMETRIC ANALYSIS OF BODY WEIGHTS

The result obtained from calculation of initial, final and weight changes of the various groups are presented in table 1.0. The final body weight for group A (Control), groups B, C, and D showed a statistically significant decrease ($P < 0.001$) The final body weight for group C treated with carbon tetrachloride was significantly higher ($P < 0.001$) than the control and other experimental groups (B,C and D) animals. The weight change for group C showed a statistically increase compared with the control and other experimental groups ($P < 0.001$).

Table 1.0: Comparison of mean initial and final body weight and weight change in all the groups (A, B, C, and D). (Mean±SEM given for each measurement)

	GP. A	GP. B	GP. C	GP. D	F-RATIO	PROB.OF SIG.
INITIAL BODY WT.	104.50±4.79	111.75±4.64	164.75±7.63	129.50±8.96	68.230	<0.0001
FINAL BODY WT.	112.50±6.60	121.50±10.66	133.25±8.53	137.75±10.01	30.510	<0.0001
WT. CHANGE	8.00±7.70	9.75±6.50	31.50±15.08	8.25±5.67	16.150	<0.0001

The weight of animals in group C were significantly higher (P<0.001) than group A (Control) and groups B, and D before administration. After the administration, the weight of animals in group A (control) and group B, and D increased statistically while the group C animals showed a significant decrease (P<0.001) compared to the weight before administration.

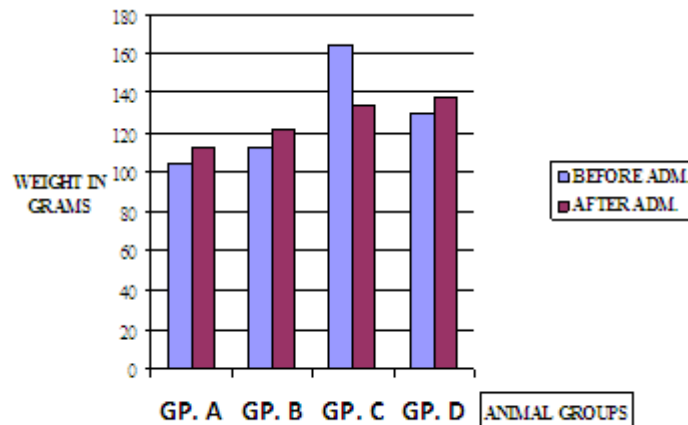


FIG1.0 WEIGHT OF ANIMALS BEFORE AND AFTER DRUG ADMINISTRATION

3.3 MORPHOMETRIC ANALYSIS OF LIVER WEIGHTS

Results obtained from calculations of relative liver weight of the various groups are presented in table 2.0. The relative liver weight for group C (carbon tetrachloride administered) were significantly higher (P<0.001) than that of the group A (control) and other experimental groups (B, and D). The values for groups B and D were similar to the group A (control)

Table 2.0: comparison of mean relative liver weight for group A (control) and experimental groups (B, C and D). (Mean ± SEM given for each measurement)

	GP. A	GP. B	GP. C	GP. D	F-RATIO	PROB. OF SIG.
LIVER WT.	4.79±0.045	4.66±0.161	7.33±0.625	4.72±0.070	53.84	<0.0001

The group C (carbon tetrachloride administered) were significantly higher ($P < 0.001$) than the control group (A) and groups B and D, as shown in Figure 2.0 below

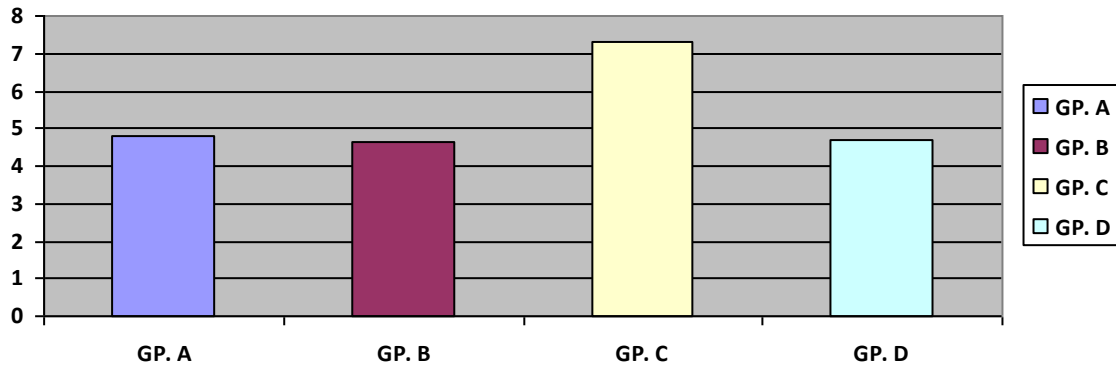


FIG 2.0 BAR CHART SHOWING THE RELATIVE LIVER WT. OF ANIMAL GROUP

3.4 HISTOPATHOLOGICAL FINDINGS

The result of the microscopic examination of the liver cells of the animal in treatment group A (control) showed normal hepatic architecture. The sinusoids are well dilated. The central vein is prominent and radially placed hepatic cells as shown in micrograph 1. Micrograph 2 shows the histology of the liver cells of the animals in treatment group B (treated with carotenoid). The micrograph shows normal hepatic architecture. The hepatocytes radiate from the central vein. The sinusoids are well dilated. Micrograph 3 shows the histology of the liver cells of the animals in treatment group C (treated with carbon tetrachloride). It shows distortion of the liver architecture. There is poor differentiation of the hepatic plates and loss of nuclei. There is also necrosis of the hepatocytes. Micrograph 4 shows the histology of the liver cells of the animals in treatment group D (treated with carotenoid + carbon tetrachloride). The micrograph shows liver architecture with mild dilation of the sinusoids. The cells are somewhat congested.

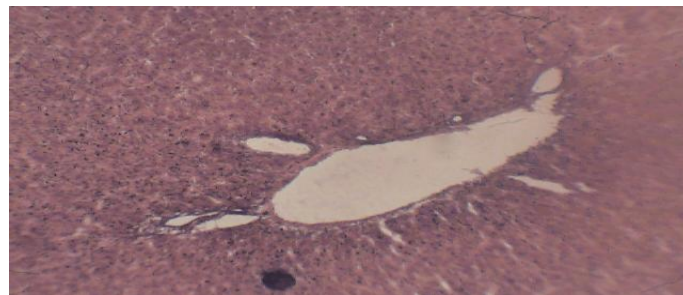


FIG 3.0: MICROGRAPH 1 (Group A – control)

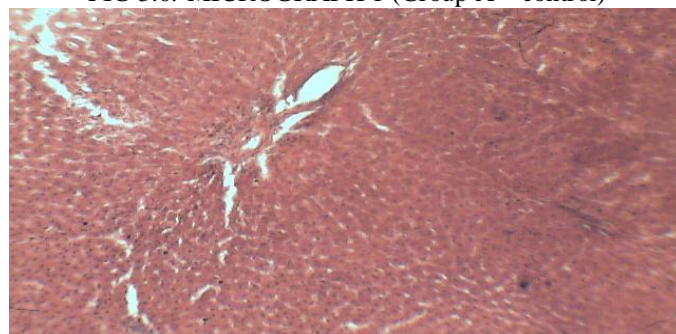


FIG 4.0: MICROGRAPH 2 (Group B- treated with carotenoid)

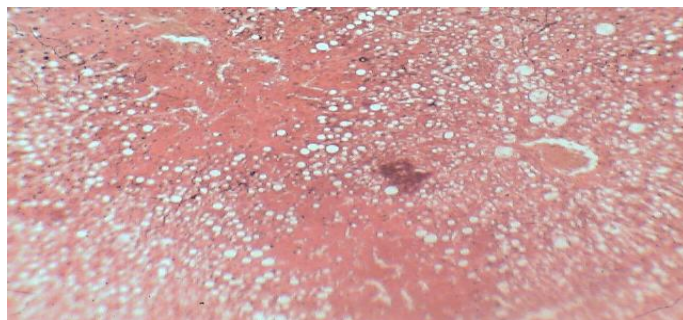


FIG 4.0 : MICROGRAPH 3 (Group C – treated with CCl₄)

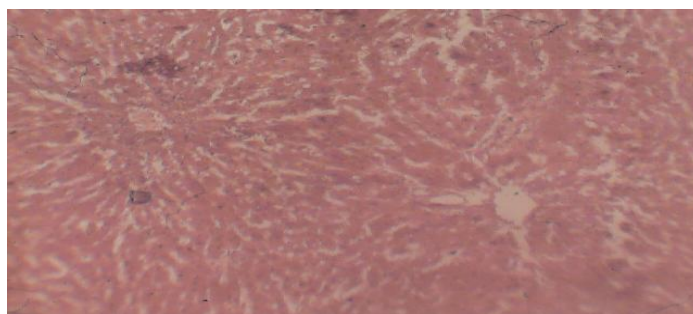


FIG 5.0 MICROGRAPH 4 (Treated with carotenoid + carbontetrachloride; Group D)

IV. DISCUSSION

Carbon tetrachloride has toxicological effect on the liver, kidney and other visceral organs. Studies on the toxic effects of this chemical on the liver have been reported^[1]. These reports have all presented carbon tetrachloride as a hepatotoxin. The results of this study agree with previous researchers that carbon tetrachloride has toxicological effect on the liver of wistar rats (*Rattus norvegicus*). The liver showed necrosis, infiltration by inflammatory cells, and congestion of the central vein and distortion of liver cell architectures. These results tend to agree with Ossowka et al^[8] that the effects of carbon tetrachloride toxicity are not easily reversible. It seems variance with Akpanabiatu et al^[2] who postulated that the effects of carbon tetrachloride toxicity on the liver were not long lasting and it was reversible. It was observed during the studies that generally, the group in which the rats were treated with carotenoid + carbon tetrachloride was able to tolerate carbon tetrachloride in their system much longer. Most of them did not show any sign of histological differences in their liver at all. This is similar to the reports by Dinis Oliveira et al^[4], and Hawazen and Al-Rawi that substances with antioxidant properties such as carotenoid would protect to a large extent against the effects of carbon tetrachloride toxicity.

Observation of the body weight difference in groups reveals gradual increase in weight of animals for the control group A. This could have been physiological as the only substance they were exposed to was water and food. Comparing the results of weight difference reveals severe loss of weight by the carbon tetrachloride exposed group. This is probably as a result of loss of appetite by the animals in the group. The groups that were treated with carotenoid only, and carotenoid + carbon tetrachloride showed increase in weight which is similar to the control group. Carotenoid in this instance functions primarily as a dietary supplement enhancing growth. The relative organ weights also showed significant differences in groups. There was relative increase in liver weight for the carbon tetrachloride exposed animals compared to the control and carotenoid treated animals. This organ weight increase was irrespective of the fact that there was total body weight loss. This could have been pathological and one may deduce that the increase in liver weight was not growth but inflammation. Antioxidant properties of carotenoid could have been responsible for the control or prevention of inflammation in the groups treated with them. The animals in group D gave a particularly interesting observation about the dynamics of reactions to the presence of various substances in our systems. On administration of carotenoid to the groups, the animals showed increase in overall body weight similar to that of the control. Administration of

carotenoid alone did not cause weight loss to the animals compared with the animals in control group. By these observations one may deduce that administration of carotenoid may boost the tolerance capacity for carbon tetrachloride induced toxicity. Thus, the protective effect of carotenoid against carbon tetrachloride induced liver damage recorded in the present study is attributed to their antioxidant properties.

V. CONCLUSION

This study has demonstrated the potential ability of carotenoid to protect against carbon tetrachloride induced toxicity in the liver of rats. Rat's tissues are very similar in many aspects to those of human. The findings of this study suggests that carotenoid administered to individuals exposed to carbon tetrachloride poisoning could provide some protection against carbon tetrachloride toxicity and perhaps ameliorate the effects of carbon tetrachloride toxicity on the liver.

VI. REFERENCES

- [1] Agency for Toxic Substances and Disease Registry (ATSDR). (2005). Toxicological profile for Carbon Tetrachloride (update). Atlanta, G.A U.S Department of Health and Human Services, Public Health Service.
- [2] Akpanabiatu M.I., Igiri A. O. Eyong E.O, Eteng M.U. (2003). Biochemical and histological effects of Eleophorbia drupifera leaf extract in wistar albino rats. *Pharm. Biol.* 41: 96-99.
- [3] Castro J. A, Ferrya, C.R, Sasame, H, (1974). Prevention of carbon tetrachloride induced necrosis by inhibitors of drugs metabolisms. Further studies on the the mechanism of their action. *Biochem Pharmacol.* 23: 295-302.
- [4] Dinis-Oliveira, R.J., Remiao, F., Carmo, H., Duarte, J.A., Navarro, A.S., Bastos, M.L., Carvalho, F., 2006a. Paraquat exposure as an etiological factor of Parkinson's disease.
- [5] Diplock A. T, Charleux G., Crozier-willi, F. S. Kok, C. Rice-Evans, M. Roberfroid, W. Stahl, J. Vina-ribes (1998). Functional food science and defence against reactive oxidative species. *British journal of nutrition*; 80, suppl. 1, S77-S112.
- [6] Eteng M.U., Ebong P.E. Ettah R.R., Umoh I. B. (1998). Aminotransferase activity of serum, liver and heart tissue of rats exposed to theobromine. *Indian J. Pharmacol.* 30: 339-342.
- [7] Hawazen A. Lamfon and Maisaa M. Al-Rawi (2007) Effect of antox on paraquat - induced histological and biochemical changes in kidney of albino rats. *J. Applied Sci. Res.* , 3 (10): 988-993.
- [8] Ossowska K, Lorenc-Koci E, Schulze G, Wolfarth S (1996) The influence of dizocilpine (MK-801) on the reserpine-enhanced electromyographic stretch reflex in rats. *Neurosci Lett* 203:73-76
- [9] Rajagopalan K., Swaragan V. V. and Varier P. R. (1994). *Curculigo orchoides* Gaertn. In *Indian medicinal plants*. Eds warrier P. K. Ramakutty C. Orunt longman, madras, Vol 2, 245-248.
- [10] Reyes-Gordillo K, Segovia J, Shibayamah, m Vergara, P, Moreno MG, Muriel P (2007): Curcumin protects against acute liver damage in the rat by inhibited NF-KB, proinflammatory cytokines production and oxidative stress. *Biochem biophys Acta.* 1170:989-996.
- [11] Selvan R. Latitha subramonian, Gayathri R, and Anyayarkani N. (1995).
- [12] Sunita Tewari, Vani Crupta and Sandeep Bhattacharya (2000). Comparative study of antioxidant potential of tea with and without additives Indi. *J. Physiol. Pharmacol.* 44 (2): 215-219. The antioxidant activity of tumeric (curcuma long) J. *Ethnopharmacol.* 47: 59-69.
- [13]